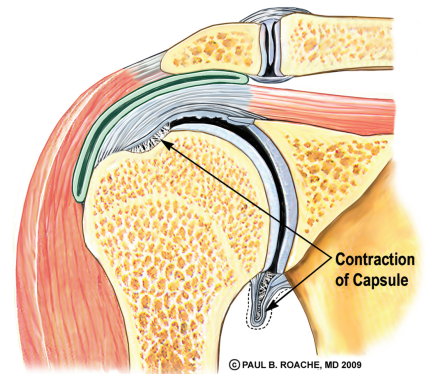
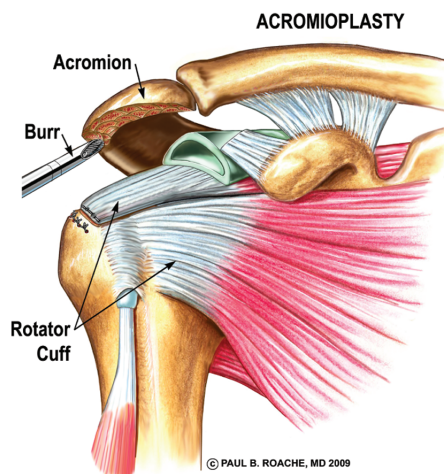
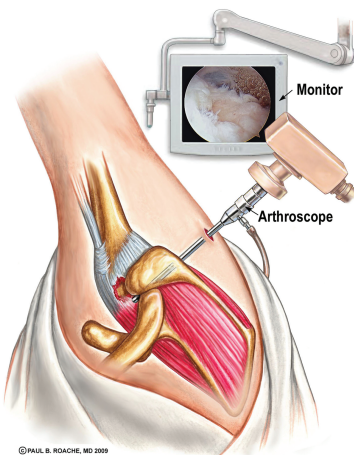
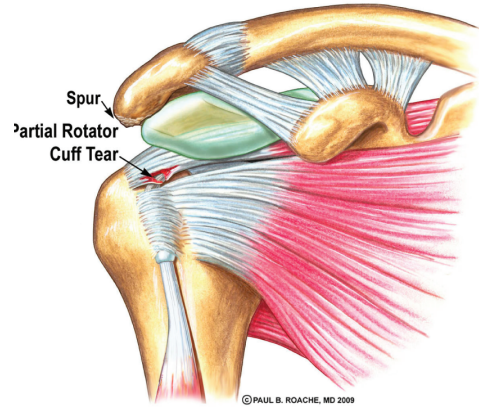
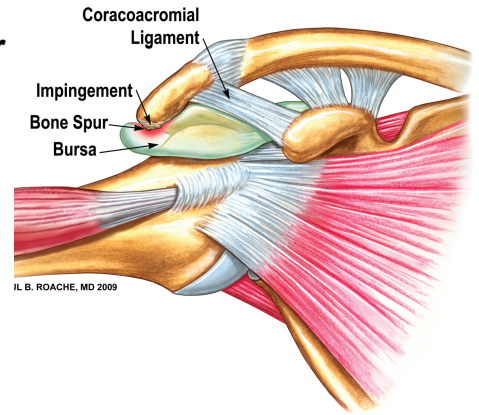
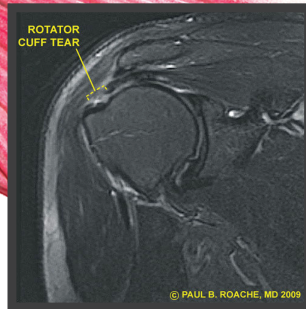
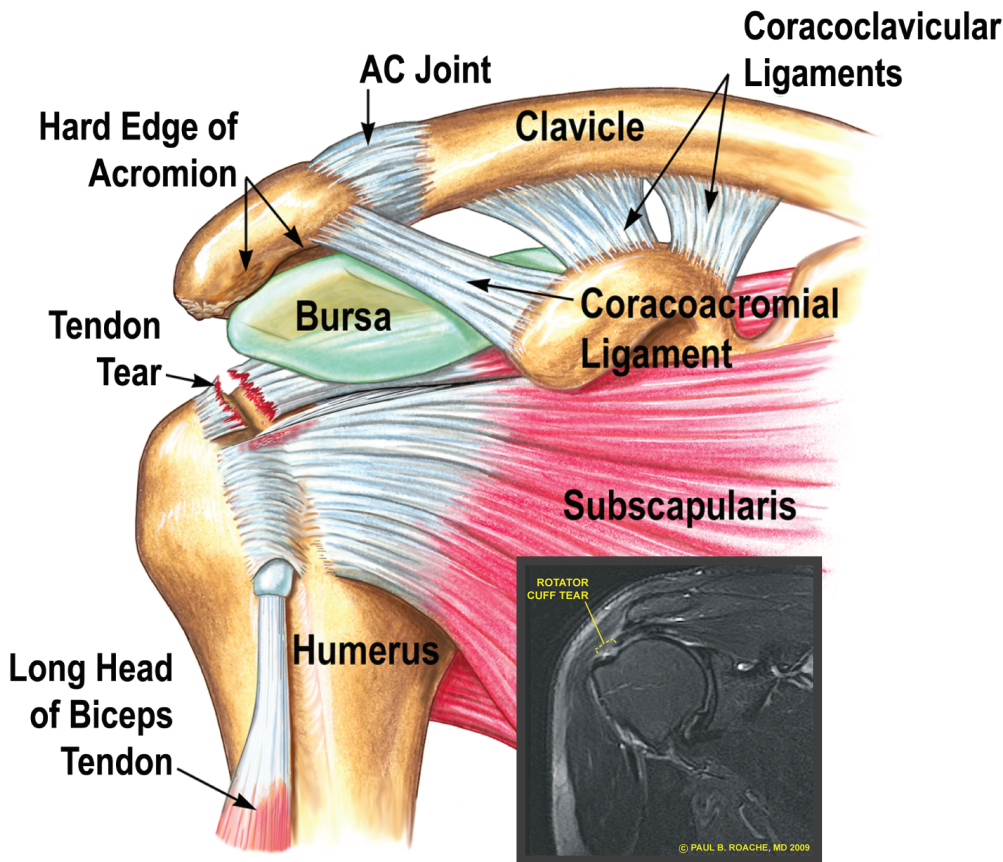
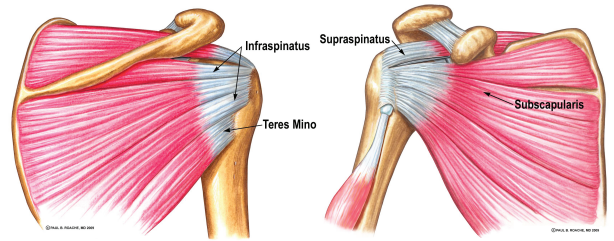
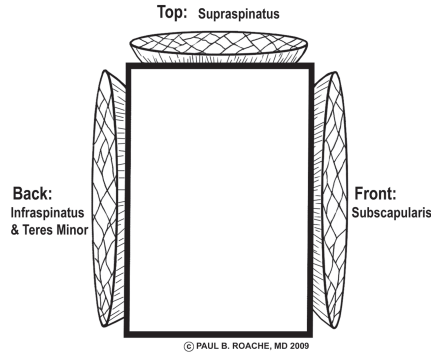
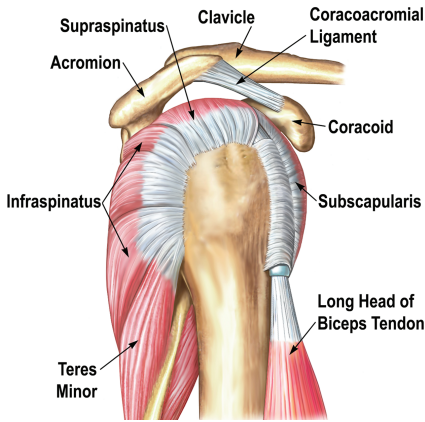


Rotator Cuff Injuries: Impingement, Inflammation, Partial and Complete Tears



ADHESIVE CAPSULITIS