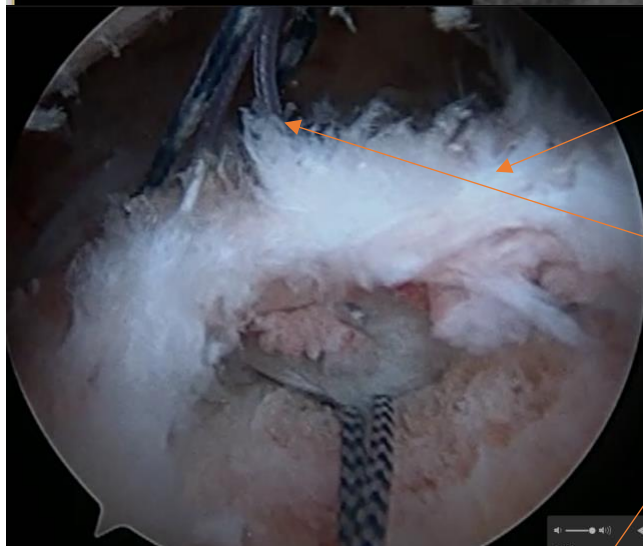
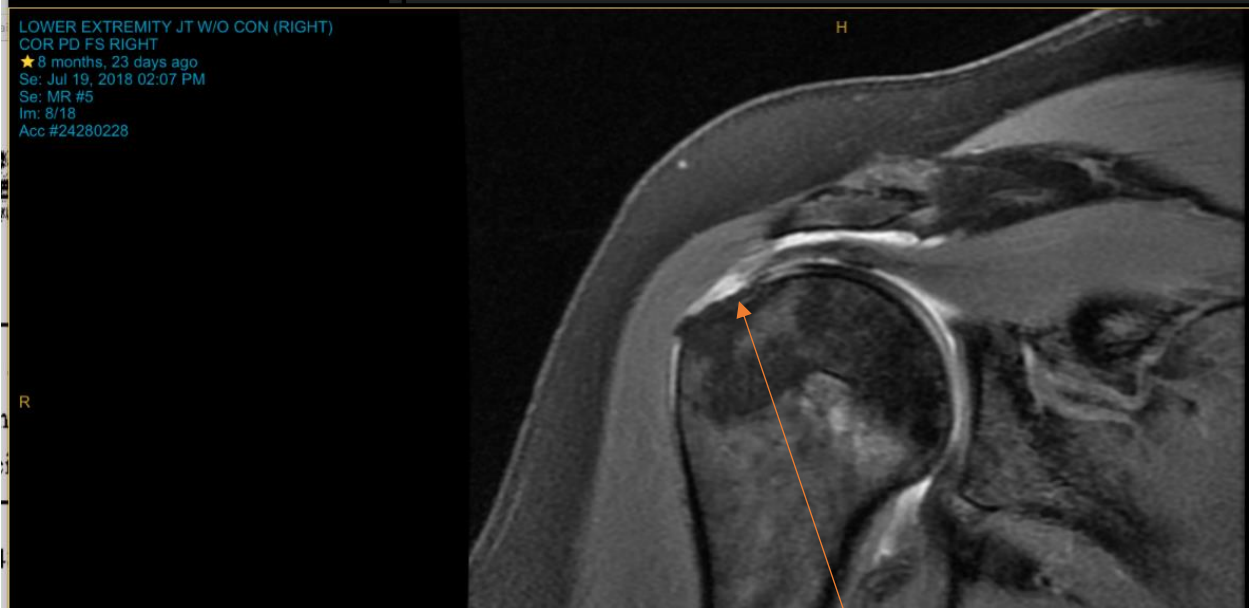

RoacheMD: Healed Right shoulder ARCR using Medium patch. 5 months postop.

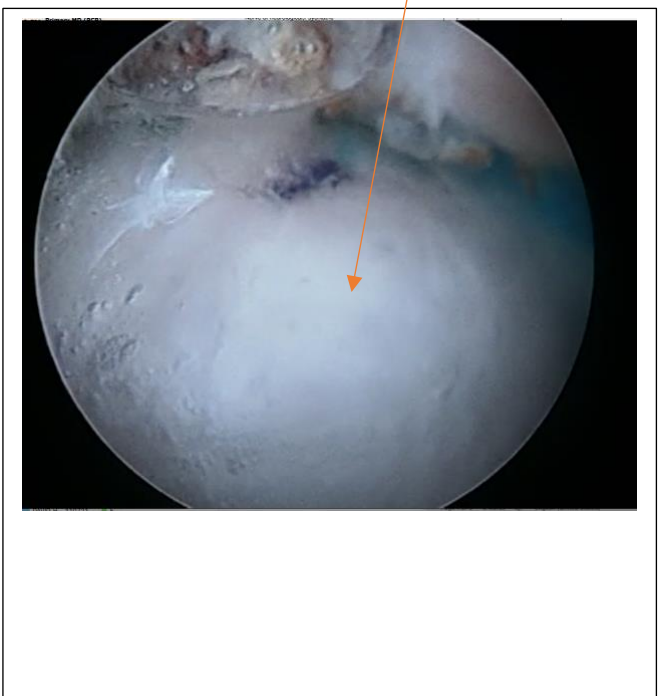
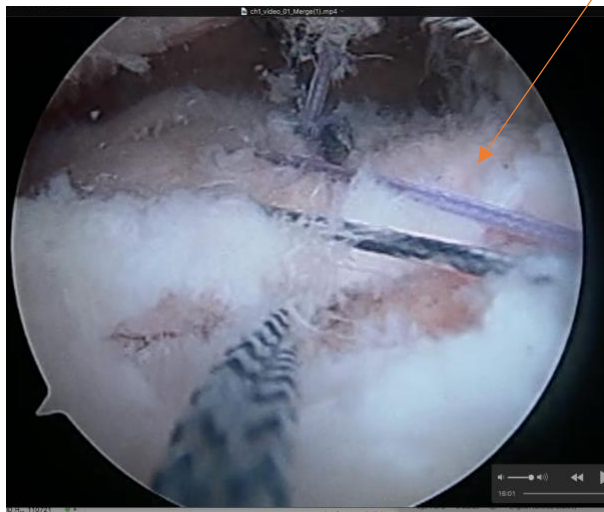


Crescent style tear.  
Anterior Cable  
completely torn

Anterior Cable repair  
sutures placed.

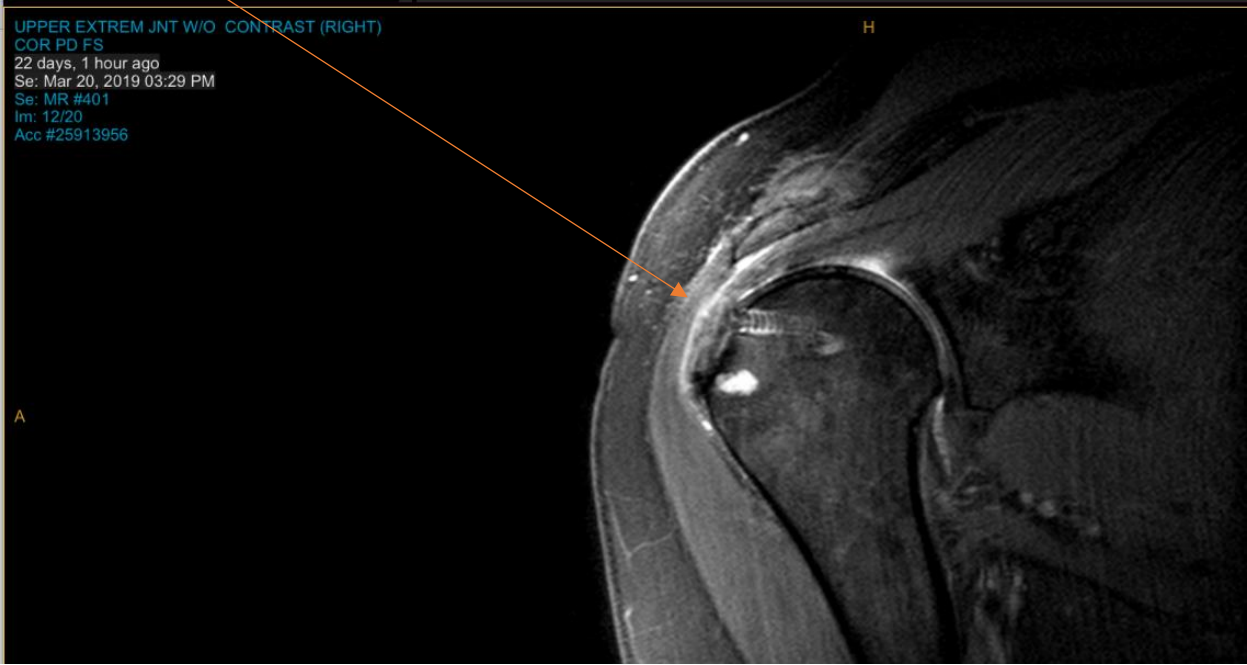
Initial reduction and trial  
repair bridged to lat  
anchor. Post anchor not  
yet placed.

Final repair covered by  
patch.

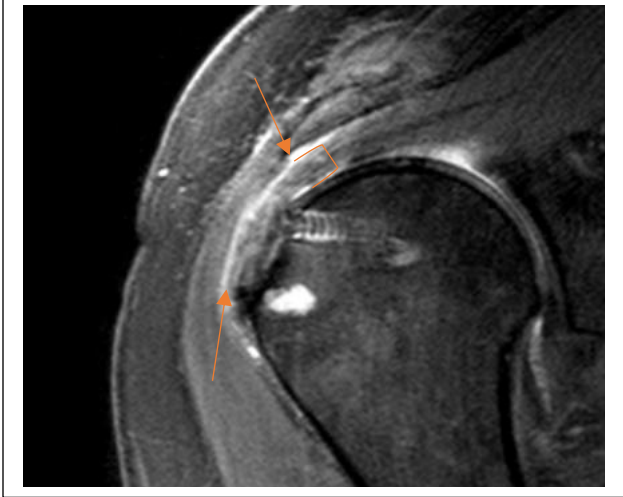


RoacheMD: Healed Right shoulder ARCR using Medium patch. 5 months postop.

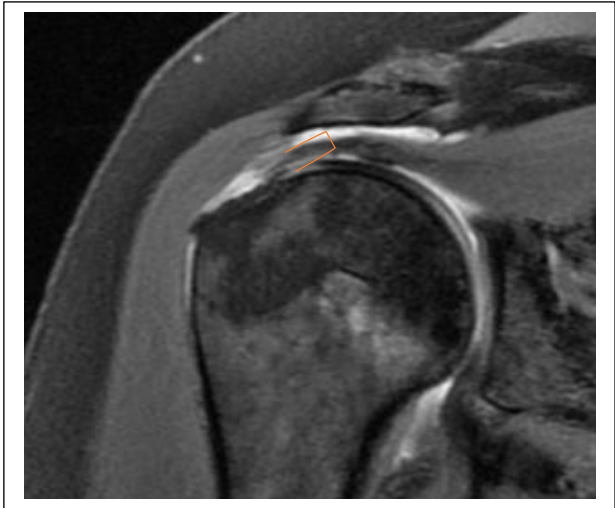
Healed repair:



Tendon like layer and increase overall thickness



pre-repair MRI as comparison.



RoacheMD: Healed Right shoulder ARCR using Medium patch. 5 months postop.

